

Mycotic Common Femoral Artery Pseudoaneurysm after Multiple Percutaneous Access in a Trauma Patient requiring Revascularization & Reconstruction

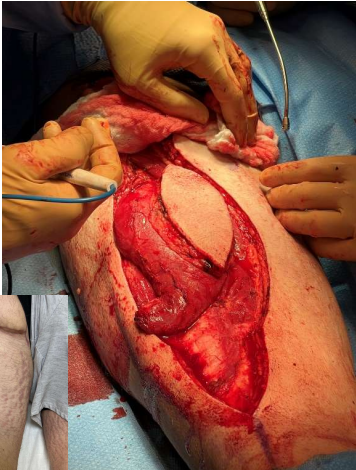
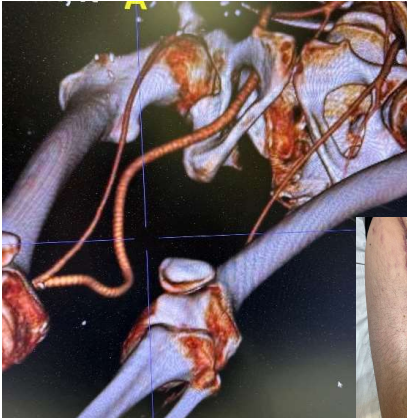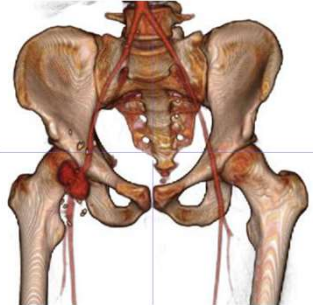
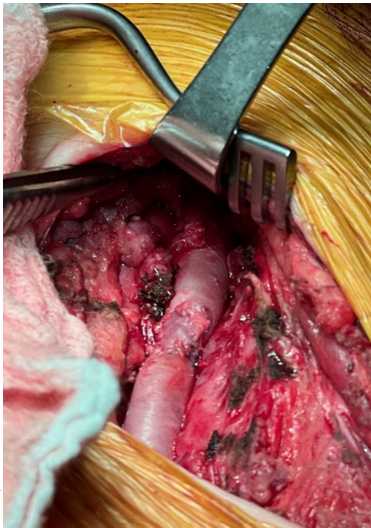
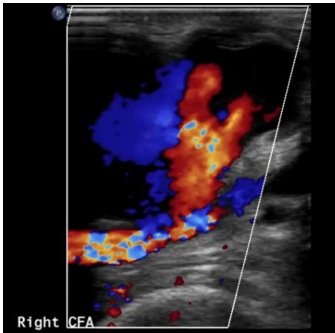
Ryan D. Gordon, MD^{a,b}; Kathryn E. Bowser, MD^a

^a: Christiana Care Hospital, 4755 Ogletown Stanton Rd, Newark, DE 19713
^b: Virginia Commonwealth University 1200 East Broad St, Richmond, VA 23298



Case Description

- 20YO M polytrauma patient after high speed MVC
- Index Injuries: Minimal intraABD, b/l pulmonary parenchymal injuries c/b caviatary collections
- Index Hospitalization Procedure:
 - Exploratory Laparotomy
 - B/L Tube thoracostomies
 - Zone 3 TEVAR (R groin access)
 - V-V ECMO (R groin cannulation)
- Return Clinic follow-up w/ pulsatile neckless R CFA PSA at clinic follow-up (8 weeks later)
 - Pulsatile 3.03x3.49cm PSA
 - R CFA PSA resection & autologous vein patch
 - POD 1 symptomatic COVID-19
 - Failed PSA patch repair w/ skin changes and associated extravasation
 - 4.1x3.8cm
 - + Enterobacter cloacae
- 2 Stage Resection & Reconstruction
 1. Sterile Obturator bypass w/ ringed PTFE to distal R SFA
 1. Ligation & excision R EIA-SFA infected segment
 2. Rectus femoris muscle flap coverage w/ Intraoperative SPY
- Follow-Up
 - Return to baseline activities and employment



Discussion

- Index: 20YO Blunt Polytrauma
- Right CFA excision & autologous vein patch repair
 - Pulsatile 3.03x3.49cm PSA
 - c/b patch failure with extravasation w/ skin changes and infection (4.1x3.8cm)
- Outcome at Follow-Up
- Returned to normal life including employment and fitness

References

1. Matthew H Samore, Mireya A Wessolossky, Stanley M Lewis, Samuel J Shubrooks, Adolf W Karchmer, Frequency, Risk Factors, and Outcome for Bacteremia After Percutaneous Transluminal Coronary Angioplasty, *The American Journal of Cardiology*, Volume 79, Issue 7, 1997, Pages 873-877, ISSN 0002-9149, [https://doi.org/10.1016/S0002-9149\(97\)00006-4](https://doi.org/10.1016/S0002-9149(97)00006-4).
2. Engin C, Posacioglu H, Ayik F, Apaydin AZ. Management of vascular infection in the groin. *Tex Heart Inst J*. 2005;32(4):529-34. PMID: 16429897; PMCID: PMC1351824.
3. Zenunaj G, Traina L, Acciarri P, Spataro C, Gasbarro V. Revascularisation through the obturator foramen of lower limbs with a compromised ipsilateral groin due to infection. *Ann R Coll Surg Engl*. 2020 Jan;102(1):14-17. doi: 10.1308/rscans.2019.0070. Epub 2019 Jun 3. PMID: 31155915; PMCID: PMC6937601.
4. Wübbeke LF, Conings JZM, Elshof JW, Scheltinga MR, Daemen JHC, Jacobs MJ, Mees BM. Outcome of rectus femoris muscle flaps for groin coverage after vascular surgery. *J Vasc Surg*. 2020 Sep;72(3):1050-1057.e2. doi: 10.1016/j.jvs.2019.11.031. Epub 2020 Feb 28. PMID: 32122734.
5. Ryer EJ, Garvin RP, Kapadia RN, Jorgensen BD, Green JO, Fluck M, Orlova K, Cindric MC, Elmore JR. Outcome of rectus femoris muscle flaps performed by vascular surgeons for the management of complex groin wounds after femoral artery reconstructions. *J Vasc Surg*. 2020 Mar;71(3):905-911. doi: 10.1016/j.jvs.2019.05.052. Epub 2019 Aug 27. PMID: 31471237.